

# Analysis of Tissue Margins of Cone Biopsy Specimens Obtained with "Cold Knife," CO<sub>2</sub> and Nd:YAG Lasers and a Radiofrequency Surgical Unit

Ralph J. Turner, M.D.  
Robert A. Cohen, M.D.  
Richard L. Voet, M.D.  
Stacy R. Stephens, M.D.  
Sheldon A. Weinstein, M.D.

*Analysis of the tissue margins of cone biopsy specimens obtained from 40 patients showed varying degrees of thermal and mechanical artifact at the tissue margins. The least artifact was seen in the tissue margins of specimens obtained with the scalpel ("cold knife"). The amount of thermal damage to biopsies obtained via lasers and the radiofrequency unit varied with the instrument*

*employed. However, the quality of the tissue margins of specimens obtained using a radiofrequency surgical unit equipped with a needle electrode on a "pure cut" setting approached the quality of those obtained with the cold knife in their lack of thermal and mechanical artifact.*

## Introduction

The outpatient treatment of abnormal cervical cytology has seen many technologic advances in the last decade. The use of lasers for vaporization and cone biopsy and the new electrosurgical devices that provide for loop excision of the abnormal cells have offered safe alternatives to the cone biopsy and the multiple techniques taught for the classic operation. Since cone biopsy was originally described by Lisfranc in 1815, the major complications of hemorrhage, infection and cervical stenosis have concerned clinicians. The difficulty in observing the squamocolumnar junction buried deep in the endocervical canal as a result of sutures for hemostasis has prompted investigators to develop and use better technologies without compromising the principles of safe medical practice.

In recent debates at our institution, the authors have sought to find a safe outpatient technique for evaluating abnormal cervical cytology and dysplasia. The ideal operation involves (1) minimal pain and discomfort, (2) minimal complication rates, especially for hemorrhage and infection, (3) satisfactory tissue margins that allow the pathologist to comment on the adequacy of the excision and (4) minimal capital investment.

## Materials and Methods

Over the past four years, the surgeons have evaluated the performance of the CO<sub>2</sub> and Nd:YAG lasers and the radiofrequency surgical unit (Ellman Corporation, Hewlett, New York) for the above criteria. The CO<sub>2</sub> laser was manufactured by Sharplan (Laser Industries, Ltd., Tel Aviv, Israel). The Nd:YAG laser was manufactured by SLT (Malvern, Pennsylvania). As the "gold standard," the "cold knife" (scalpel) cone was employed because of its outstanding attributes: excellent tissue margins and minimal expense. The specimens from 20 cold knife conizations, 11 CO<sub>2</sub> laser cone biopsies, 3 cone biopsies performed with

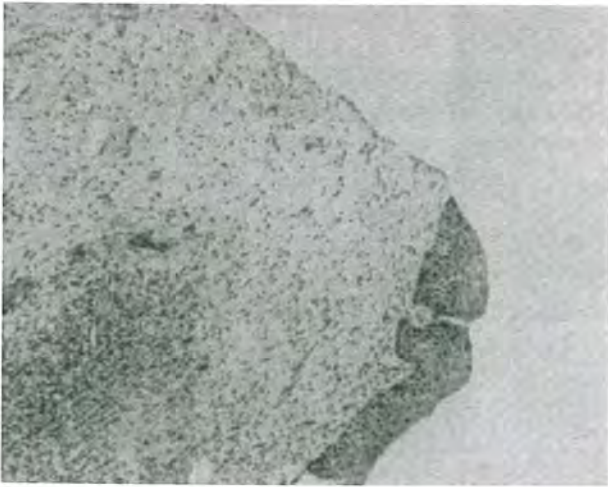
From the Departments of Obstetrics and Gynecology and of Pathology, Presbyterian Hospital of Dallas and University of Texas Southwestern Medical School, Dallas, Texas.

Dr. Turner is in the Department of Obstetrics and Gynecology. Dr. Cohen is Clinical Assistant Professor, Department of Obstet-

rics and Gynecology.

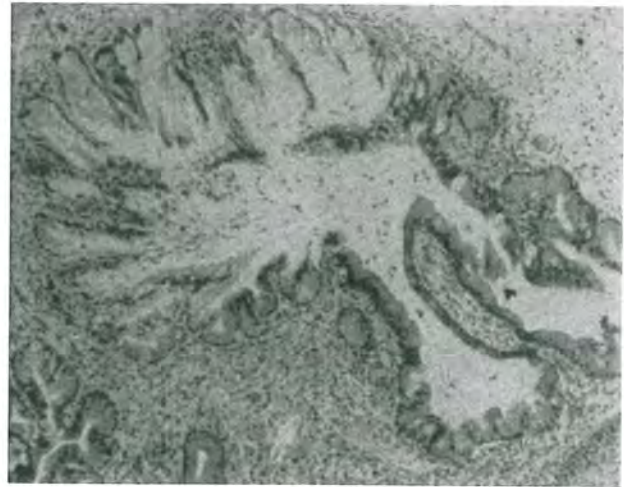
Dr. Voet is Clinical Assistant Professor, Departments of Obstetrics and Gynecology and of Pathology.

Drs. Stephens and Weinstein are Clinical Professors, Department of Obstetrics and Gynecology.



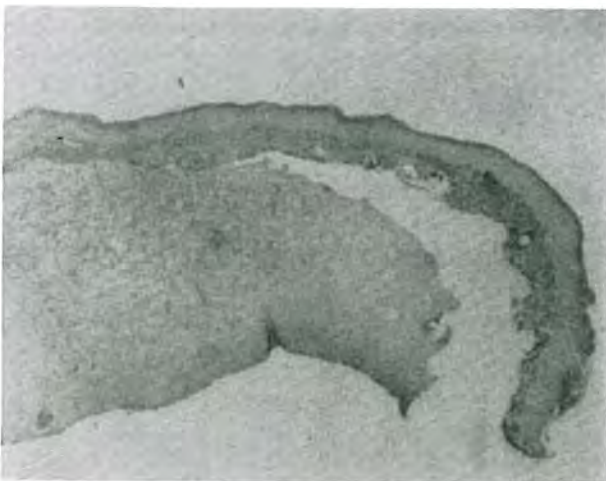
**Figure 1**  
Cone biopsy specimen obtained by scalpel.

the SLT laser, and 6 cone biopsies by radiofrequency excision (3 with a needle electrode and 3 with a loop device) were examined for adequacy of tissue margins. In those cases in which the cone biopsy was obtained by the loop excision technique, the actual time required for the loop excision to be performed was less than 10 seconds. The ongoing concern expressed by the study team pathologist was that the ideal specimen should not have any mechanical and/or thermal artifact that would interfere with interpretation of the involvement of the tissue margins with dysplasia or cancer.

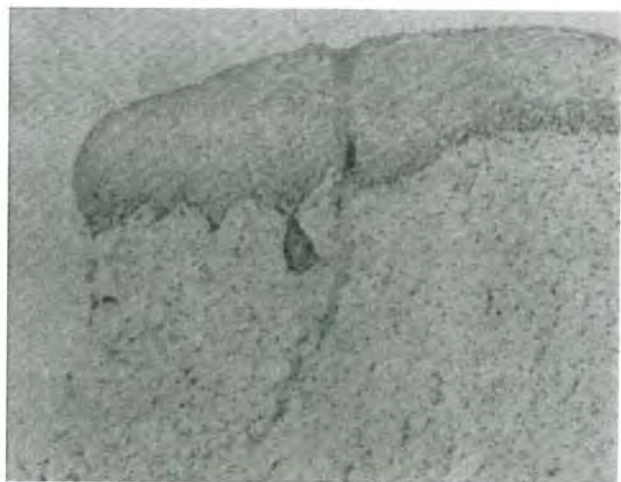

**Figure 3**  
Polarization of the nuclei of the endocervical glands and distention and distortion of endocervical glands with the radiofrequency unit loop.

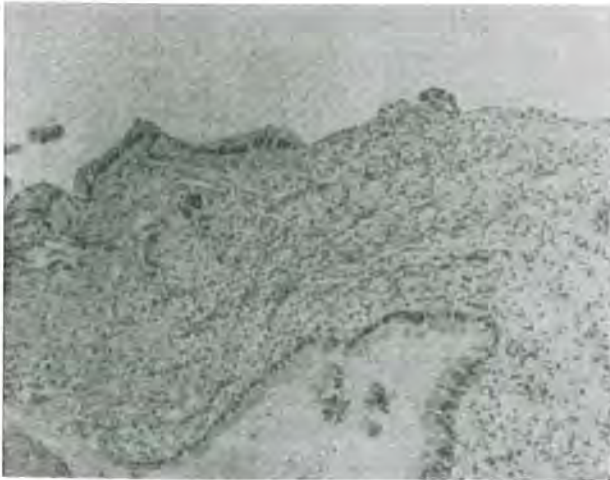Patients requesting treatment in the ambulatory surgery center were usually given light inhalation anesthesia and supplemental intravenous sedation. A paracervical block of 1% lidocaine was frequently used alone or with the inhalation agents. To achieve hemostasis, pitressin was administered in accordance with the guidelines of Harper et al,<sup>1</sup> who described cardiovascular changes as common when less than 1 unit of pitressin was administered. Harper showed that 0.5–0.75 units gave satisfactory hemo-



**Figure 2**  
Detachment of epithelium from the underlying stroma as mechanical artifact.



**Figure 4**  
Almost ideal tissue margins obtained with needle electrode and the radiofrequency unit.

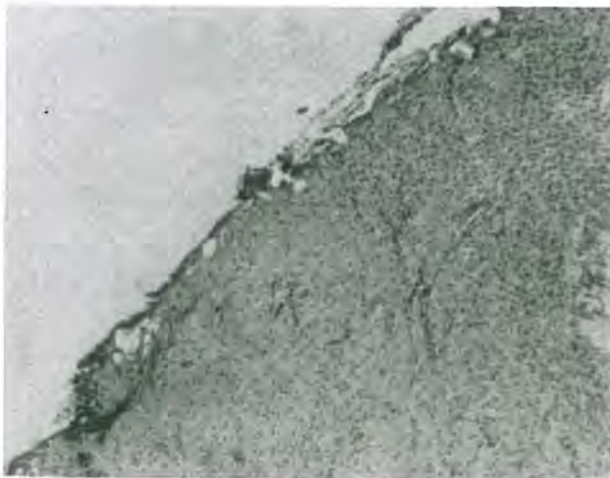


**Figure 5**  
No significant tissue distortion or coagulation resulting from use of the radiofrequency needle electrode.

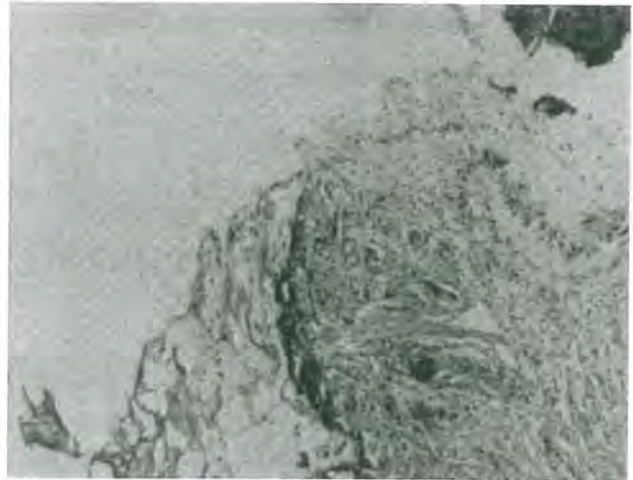stasis when the pitressin solution was injected submucosally. In our study the solution was mixed by the surgeon to give 1 unit of pitressin per 5 mL of normal saline.

### Results

This investigation was designed to evaluate the strengths and weaknesses of the four methods and to determine whether the newly available radiofrequency surgical unit would fulfill the criteria for safety, low complication rate, patient acceptance, satisfactory tissue margins and minimal expense. The



**Figure 6**  
Thermal artifact at the margin of cone biopsy obtained by SLT.



**Figure 7**  
Char and significant thermal artifact at margin of CO<sub>2</sub> laser cone biopsy.

least thermal and mechanical damage is seen in the cold knife specimens which are therefore best for tissue analysis. One does not have the problem of having the dysplastic process running into the edge of the specimen that has been obliterated by coagulation necrosis or carbon char (Figure 1).

When using the radiofrequency unit, which employs both a loop and a needle electrode, the pathologist notes the occasional detachment of the epithelium from the underlying stroma (Figure 2). Another occasional finding with the loop electrode is polarization of the nuclei of the endocervical glands and distention and distortion of the endocervical glands (Figure 3). In extreme cases in which the electrode is moved through the tissue in a very slow fashion, one may see coagulation necrosis at the tissue margin. The needle electrode used on a pure cut at a setting of about "4" does not show this artifact. In fact the tissue margins shown in Figure 4 are almost indistinguishable from those obtained with the cold knife. In Figure 5, the endocervical margin shows no significant tissue distortion or coagulation. Use of the scalpel attachment on the SLT (Figure 6) produced a specimen with significant thermal artifact. The CO<sub>2</sub> laser used to obtain the specimen in Figure 7 also shows significant char and artifact.

### Discussion

We believe that we have demonstrated the efficacy of the radiofrequency unit for cone biopsies. The surgeon must understand the instruments' effect on the

tissue and therefore must match the tissue effects to the requirements of the pathophysiologic principles of the disease being treated. If the surgeon is able to obtain a sufficiently wide margin of normal tissue between the dysplasia on the cervix and the surgical tissue margins, mechanical distortion, coagulation necrosis or char will not interfere with the pathologist's interpretation.

The cost efficiency of the radiofrequency unit we have used is exceptional—as much as 10–40 times that of lasers. Speed and ease of performance are definite advantages of the loop excision technique with the radiofrequency surgical unit.

With the radiofrequency unit, one does not need a ground return pad. The unit uses an antenna which acts as a return electrode and should be placed under the operative field. This surgical unit operates at 3.8 MHz as opposed to the 0.5–1 MHz range of other electro-surgical units. Its effect on tissue is that of dissecting an envelope of steam around the electrode as it passes rapidly through the tissue. Tissues with


higher water content are dissected more easily than those with less water content. This accounts for the favorable experience when used on the cervix.

### Conclusion

When cone biopsy specimens were obtained with the radiofrequency surgical unit at a pure cut setting of 4 and with pitressin as a hemostatic agent, the resultant tissue margins' lack of artifact and thermal damage was comparable to those of cone biopsies obtained by the cold knife in the hands of an experienced surgeon. We recommend the radiofrequency surgical unit for outpatient use in obtaining cone biopsies on the basis of the acceptability of its tissue effects, its inexpensive technology and its inherent safety.

### References

1. Harper CA Jr, Brown WE, Workman WW: Pitressin hemostasis in conization biopsy of the cervix. *Obstet Gynecol* 30:70, 1967



**Figure 8**  
Clinical set-up of Surgitron and Vapor-Vac on SurgiCart.